

## Cystoid macular oedema after phacoemulsification with and without type 2 diabetes mellitus; a hospital-based clinical prospective trial in Karachi

Abdul Haleem, Aziz-ur-Rehman, Adil Saleem, Saleh Memon, Nasir Memon, Muhammad Faisal Fahim

### Abstract

**Objective:** To know the outcomes of cystoid macular oedema after phacoemulsification in patients with and without type 2 diabetes mellitus using optical coherence tomography.

**Methods:** This non-concurrent, clinical, prospective study was carried out at Al-Ibrahim Eye Hospital, Karachi, from January to August 2015. After phacoemulsification with injectable posterior chamber intraocular lens implantation, eyes of patients were analysed. The patients were divided into diabetic and non-diabetic groups visual acuity, optical coherence tomography and dilated fundus examination were performed preoperatively (baseline) and post-operative 1st week and 6th week. SPSS 20 was used for data analysis.

**Results:** Of the 100 subjects, there were 50(50%) each in diabetic and non-diabetic group. Subsequently, 14(14%) patients were lost to follow-up, and 86 eyes of 86(86%) patients were analysed. Of them, 37(43%) were male and 49(57%) were female. The mean age of participants was  $52.21 \pm 7.43$  years (range: 38-62years). The non-diabetic group had 41(47.7%) patients and the diabetic group had 45(52.3%). There was no clinically significant cystoid macular oedema in either group. Central foveal thickness  $\geq 43.94 \mu\text{m}$  was observed in 1(2.5%) eye in the non-diabetic group and in none in the diabetic group at 1st post-operative week. At the 6th post-operative week, none of eyes in the non-diabetic group and 2(4.44%) eyes of the diabetic group showed macular oedema. There was no statistically significant difference in mean foveal volume between both groups at 1st week ( $p=0.896$ ) and 6th week ( $p=0.230$ ).

**Conclusion:** Cystoid macular oedema after phacoemulsification was equally present in both diabetics and non-diabetics without any retinopathy.

**Keywords:** Cystoid macular oedema, Diabetes mellitus, Clinical prospective trial. (JPMA 67: 395; 2017)

### Introduction

Cystoid macular oedema (CMO) is a serious consequence of cataract surgery which results in transient or even permanent loss.<sup>1</sup> The extracellular fluid is accumulated in the outer plexiform and inner nuclear layers of the retina resulting from a breakdown of the blood retinal barrier in response to post-operative inflammation in the anterior chamber.<sup>2-5</sup> CMO can be detected by clinical examination, fundus fluorescein angiography (FFA) and optical coherence tomography (OCT). Of these examinations, the OCT has the highest sensitivity.<sup>6-9</sup> The definition of clinical CMO is slightly different amongst authors, but it is generally described as visual acuity (VA) less than 0.3 logMAR with parallel bio-microscopic retinal findings of macular thickening and angiographic peri-foveal leakage.<sup>10</sup> The incidence of subclinical CMO after uneventful cataract extraction is 41 percent and 30 percent as measured by OCT and FFA, respectively.<sup>11</sup> The incidence of CMO is more in diabetics than non-

diabetics.<sup>12-14</sup> The CMO detected by advance methods does not always correlate with visual acuity.<sup>15,16</sup>

The current study was planned to determine the outcomes of CMO after phacoemulsification in patients with and without type-2 diabetes mellitus (T2DM) using OCT.

### Patients and Methods

This non-concurrent, clinical, prospective study was carried out at Al-Ibrahim Eye Hospital (AIEH), Karachi, from January to August 2015. The sample size was calculated prior to study enrolment, using an online software, Raosoft.com.<sup>17</sup> The alpha value was 0.05 at 80% power and response distribution was 50%. Patients were randomly selected from diabetes clinic and general outpatient department (OPD). Diabetic and non-diabetic patients with translucent enough cataract to allow the pre-operative fundus examination and baseline OCT were included. Criteria for exclusion were small pupils, pseudo exfoliation syndrome, history of uveitis, glaucoma, macular degeneration, the presence of diabetic retinopathy (DR) in diabetic patients and any complication during phacoemulsification.

After approval from the institutional ethics review

Al-Ibrahim Eye Hospital, Isra Postgraduate Institute of Ophthalmology, Gaddap Town Malir, Karachi.

**Correspondence:** Abdul Haleem. Email: haleem\_mirani@yahoo.com

committee, informed consent was obtained from all the participants. Age, gender and laterality were recorded. Glycated haemoglobin (HbA1c) of the diabetic group was recorded before surgery. In addition to the cataract surgery, the study involved 4 visits: 1st recruitment visit with pre-operative examination within 1 week before surgery, and post-operative visits after 1 day, 1 week and 6 weeks. On each visit, best-corrected visual acuity (BCVA) on logMAR chart and dilated fundus examination was performed. All the patients were operated by single surgeon on topical anaesthesia (proparacaine hydrochloride ophthalmic solution 0.5% USP) through phacoemulsification with injectable posterior chamber intraocular lens implantation. Central foveal thickness (CFT) and mean foveal volume (MFV) on OCT (SD 3D OCT-2000 Topcon®) was recorded at pre-operative, and 1st and 6th week post-operative follow-up. Both study groups received topical dexamethasone 0.1% and moxifloxacin 0.5% eye drops 8 times during the 1st week and dexamethasone 0.1% 4 times for the next 6 weeks post-operatively.

Primary outcome was the change in CFT at respective weeks after cataract surgery compared with baseline in both groups. Increase in CFT more than 2 standard deviations (SD) of mean pre-operative CFT of the control group (non-diabetic group) was considered macular oedema (MO).<sup>15,18,19</sup>

SPSS 20 was used for data analysis. Continuous variables were presented as mean  $\pm$ SD. Categorical variables were shown in frequency and percentages. For comparison between CFT and mean foveal thickness (MFT) at baseline, 1 week and 6 weeks, paired sample T-test was applied to see the significance.  $P < 0.05$  was considered statistically significant.

## Results

Of the 100 participants, there were 50(50%) each in diabetic and non-diabetic group. Subsequently, 14(14%)

patients were lost to follow-up. As such, the study comprised, 86 eyes of 86(86%) patients. Of them, 37(43%) were male and 49(57%) were female. The overall mean age was  $52.21 \pm 7.43$  years (range: 38-62 years). The non-diabetic group had 41(47.7%) patients and the diabetic group had 45(52.3%).

In the control group, the mean pre-operative logMAR BCVA was  $0.85 \pm 0.35$ . The value was  $0.15 \pm 0.13$  after the 1st post-operative week and  $0.07 \pm 0.09$  at the 6th post-operative week. In diabetic patients, the mean pre-operative logMAR BCVA was  $0.91 \pm 0.28$ , 1st post-operative week  $0.22 \pm 0.15$  and on 6th post-operative week  $0.17 \pm 0.13$ . The post-operative BCVA was better in the non-diabetic group than the diabetic group at 1st week and 6th week. There was statistically significant difference in logMAR BCVA between both groups at 1st week ( $p=0.015$ ) and 6th post-operative ( $p=0.000$ ) follow-ups (Table-1).

The mean CFT of the non-diabetic group was  $234.88 \pm 21.97 \mu\text{m}$  before operation,  $240.85 \pm 22.26 \mu\text{m}$  at 1st postoperative week and  $239.27 \pm 22.56 \mu\text{m}$  at 6th post-operative week. The mean CFT for the diabetic group was  $227.93 \pm 19.96 \mu\text{m}$  before operation,  $231.29 \pm 19.98 \mu\text{m}$  at 1st post-operative week and  $239.98 \pm 21.73 \mu\text{m}$  at 6th post-operative week. There was statistically significant difference in mean CFT at 1st postoperative week between the groups ( $p=0.039$ ). Non-diabetic patients showed increase in mean CFT at 1st week. But there was no statistically significant difference in mean CFT at 6th post-operative week between the groups ( $p=0.882$ ) (Table-2).

The mean increase in post-operative CFT from the baseline CFT in the control group was  $8.73 \pm 11.69 \mu\text{m}$  (maximum  $52 \mu\text{m}$ ) at 1st week and  $6.53 \pm 9.23 \mu\text{m}$  (maximum  $31 \mu\text{m}$ ) at 6th week. In the diabetic group, CFT at 1st week was  $6.37 \pm 9.27 \mu\text{m}$  (maximum  $39 \mu\text{m}$ ) and  $13.28 \pm 13.91 \mu\text{m}$  (maximum  $49 \mu\text{m}$ ) at 6th week. There was

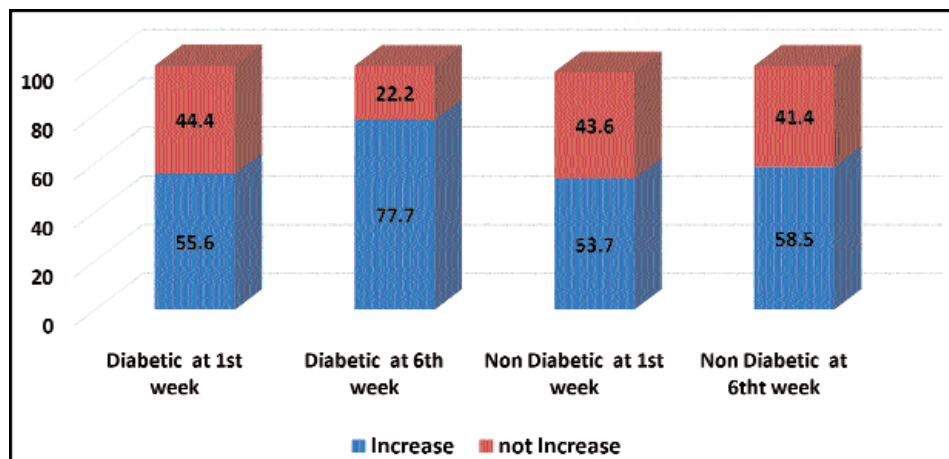
**Table-1:** Mean preoperative log MAR BCVA.

Category	Pre-operative	1st week post-operative	6th week post-operative
Non-diabetic	$0.85 \pm 0.35$	$0.15 \pm 0.13$	$0.07 \pm 0.09$
Diabetic	$0.91 \pm 0.28$	$0.22 \pm 0.15$	$0.17 \pm 0.13$

BCVA: Best-corrected visual acuity.

**Table-2:** Mean central foveal thickness (CFT).

Category	Pre-operative	1st week post-operative	6th week post-operative
Non Diabetic	$234.88 \pm 21.97 \mu\text{m}$	$240.85 \pm 22.26 \mu\text{m}$	$239.27 \pm 22.56 \mu\text{m}$
Diabetic	$227.93 \pm 19.96 \mu\text{m}$	$231.29 \pm 19.98 \mu\text{m}$	$239.98 \pm 21.73 \mu\text{m}$



**Figure:** Increase in central foveal thickness at 1st week & 6th week.

statistically significant difference between mean increase in CFT at 6th post-operative ( $p=0.010$ ) between the groups, but at 1st week the difference was statistically insignificant ( $p=0.302$ ).

In the control group, 22(53.7%) patients showed increased CFT after 1st week and 24(58.5%) showed increase of CFT after 6 weeks. By contrast, the diabetic group showed increased CFT in 25(55.6%) patients after 1st week and 35(77.8%) patients after 6th week. There was no statistically significant change in CFT of both groups at 1st week ( $p=0.571$ ) and at 6th week ( $p=0.158$ ) (Figure).

There was no clinically significant CMO in either group. Only 1(2.4%) eye in the control group developed macular oedema (thickness  $\geq 43.94 \mu\text{m}$  2 SD of non-diabetic group baseline value) at 1st post-operative week and none of the eyes at 6th post-operative week. In the diabetic group, none of the eyes showed macular oedema (thickness  $\geq 43.94 \mu\text{m}$  2 SD of control group baseline value) at 1st week post-operatively, but 2(4.44%) showed macular oedema at 6th post-operative week.

The MFV of control group was  $7.39 \pm 0.34$  pre-operatively and  $7.57 \pm 0.40$  and  $7.57 \pm 0.43$  at 1st and 6th week post-operatively, showing mean change in MFV of  $0.20 \pm 0.24$  at 1st week and at  $0.20 \pm 0.24$  at 6th week. In comparison, the diabetic group showed pre-operative MFV of  $7.42 \pm 0.38$ , and  $7.61 \pm 0.38$  and  $7.68 \pm 0.38$  at 1st and 6th week post-operatively, showing mean change in MFV of  $0.20 \pm 0.25$  at 1st week and  $0.26 \pm 0.21$  at 6th week. As such, there was no statistically significant difference in MFV between both groups at 1st week ( $p=0.896$ ) and 6th week ( $p=0.230$ ).

## Discussion

In this study, spectral domain OCT (SD-OCT) was used to

evaluate changes in macular thickness from pre-operative thickness and post-operative thickness at 1st week and 6th week. The non-diabetic group showed slightly more change in macular thickness than the diabetic group at 1st post-operative week which was statistically insignificant ( $p=0.302$ ). But at the 6th post-operative week the diabetic group showed statistically significant ( $p=0.010$ ) increase in central foveal thickness than the non-diabetic group.

In this study, none of patients showed typical cystoid appearance of macula on OCT, but there was diffuse macular thickening in patients that showed increase in central foveal thickness up to the 6th week post-operative follow-up. That means the patients had sub-clinical CMO instead of clinical CMO.

One patient in the control group (2.5%) developed significant macular oedema (thickness  $\geq 43.94 \mu\text{m}$ , 2 SD of non-diabetic group baseline value) at 1st post-operative week, whereas none of the eyes had oedema at 6th week. In the diabetic group, none of the patients developed oedema at 1st week, but 2 patients (4.44%) developed significant macular oedema at 6th week.

Slight increase of CFT  $\geq 21.97 \mu\text{m}$  (1 SD of non-diabetic group baseline value) was observed at 1st and 6th post-operative weeks in non-diabetics/diabetics in 3(7.31%)/4(8.88%) eyes and 4(9.75%)/7(15.55%) eyes, respectively, which was not a significant increase in CFT.

These results were similar to more recent studies that used OCT to evaluate progression of MO following cataract surgery. Blanco C. TF et al.<sup>15</sup> found no clinical evidence of CMO in the non-diabetic group, although 4(1.92%) eyes showed macular thickness equal to or greater than  $43.74 \mu\text{m}$  (2 SD of the basal value). In the diabetic group, clinical evidence of CMO was found in 6(14.2%) eyes with decreased visual acuities. Other studies, however, reported rates of MO progression from other methods in diabetic and non-diabetic patients separately; for example, Montes J. et al. reported that angiographic CMO was 9% of the eyes after cataract surgery using fluorescein angiography in people without diabetes.<sup>16</sup> Romero-Aroca reported that 6.06% of 132 eyes of diabetic patients developed diabetic macular oedema

(DMO) on evaluation by fluorescein angiography and OCT following uneventful phacoemulsification.<sup>20</sup> Kim et al. reported in a study of 50 eyes the incidence rate of 22% (95% confidence interval (CI): 13-35%) for DMO exacerbation (defined as at least a 30% increase in OCT centre point thickness compared with pre-surgical OCT) one month after cataract surgery. Cystoid abnormalities were seen in all progressing eyes on OCT.<sup>14</sup> Baker CW, Almkhatar T. et al. reported in a study that none of the eyes without DMO at baseline in diabetic patients developed central-involved MO (upper limit of 95% CI: 20%).<sup>18</sup>

A number of studies have reported that diabetic patients seemed to have a greater predisposition to developing CMO or to a worsening of the existing one, but they did not observe this in relation to glycaemic control and had not confirmed this tendency.<sup>12-26</sup>

Decrease visual acuity may relate to corneal oedema, posterior capsular wrinkling and corneal astigmatism. The visual outcome was better in the non-diabetic group (0.07±0.09) than the diabetic group (0.17±0.13) on 6th post-operative week. Not surprisingly, after phacoemulsification the majority of patients gained good BCVA in both groups. BCVA was generally attained in a larger proportion of patients undergoing cataract surgery among patients without diabetes. Our study showed similar results. Somaiya et al.<sup>21</sup> reported that 82% of 106 diabetic eyes achieved vision of 20/40 [LogMAR 0.3] after phacoemulsification in a retrospective review. Also, 95% of 55 non-diabetic achieved vision of 20/40 [LogMAR 0.3] in the same study.<sup>15</sup> In another study, Carl W. Baker et al.<sup>18</sup> reported 20/40 [LogMAR 0.3] or better vision occurred less often in eyes that developed central-involved MO (67%). However, these eyes had a lower mean baseline VA (60 letter score [LogMAR 0.5]) than eyes that did not develop central-involved MO (67 letter score [LogMAR 0.4]). Authors have also reported less improvement of visual acuity in diabetic eyes than non-diabetic counterparts.<sup>22</sup>

One of the limitations of the current study was the small sample size because of its short duration. This was an ongoing study in the outpatient department of the AIEH. As such, whoever gave consent to be included in this study after meeting all inclusion and exclusion criteria were included.

## Conclusion

CMO after phacoemulsification was equally present in both diabetics and non-diabetics without any retinopathy. However, the role of glycaemic control needs to be investigated in post-operative CMO.

**Disclaimer:** None.

**Conflict of Interest:** None.

**Source of Funding:** None.

## References

- Loewenstein A, Zur D. Postsurgical cystoid macular edema. *Dev Ophthalmol.* 2010; 47:148-59.
- Lobo CL, Faria PM, Soares MA, Bernardes RC, Cunha-Vaz J. Macular alterations after small incision cataract surgery. *J Cataract Refract Surg.* 2004; 30:752-60.
- Flach AJ. The incidence, pathogenesis and treatment of cystoid macular edema following cataract surgery. *Trans Am Ophthalmol Soc.* 1998; 96:557-634.
- Miyake K, Ibaraki N. Prostaglandins and cystoids macular edema. *Surv Ophthalmol.* 2002; 47:S203-18.
- Bringmann A, Reichenbach A, Wiedemann P. Pathomechanisms of cystoids macular edema. *Ophthalmic Res.* 2004; 36:241-9.
- Antcliff RJ, Stanford MR, Chauhan DS, Graham EM, Spalton DJ, Shilling JS, et al. "Comparison between optical coherence tomography and fundus fluorescein angiography for the detection of cystoid macular edema in patients with uveitis." *Ophthalmology.* 2000; 107:593-9.
- Ouyang Y, Keane PA, Sadda SR, Walsh AC. Detection of Cystoid Macular Edema with Three-Dimensional Optical Coherence Tomography versus Fluorescein Angiography. *Invest Ophthalmol Vis Sci.* 2010; 51:5213-8.
- Jitpoonkuson T, Garcia PM, Rosen RB. Correlation between fluorescein angiography and spectral-domain optical coherence tomography in the diagnosis of cystoid macular edema. *Br J Ophthalmol.* 2010; 94:1197-200.
- Biro Z, Balla Z. Foveal and perifoveal retinal thickness measured by OCT in diabetic patients after phacoemulsification. *cataract surgery. Ophthalmologia.* 2009; 53:54-60.
- Chaudhary C, Bahadur H, Gupta N. Study of cystoid macular edema by optical coherent tomography following uneventful cataract surgery. *Int Ophthalmol.* 2015; 35:685-91.
- Kim SJ, Belair ML, Bressler NM, Dunn JP, Thorne JE, Kedhar SR, et al. A method of reporting macular edema after cataract surgery using optical coherence topography. *Retina.* 2008; 28:870-6.
- Pollack A, Leiba H, Bukelman A, Oliver M. Cystoid macular oedema following cataract extraction in patients with diabetes. *Br J Ophthalmol.* 1992; 76:221-4.
- Brito PN, Rosas VM, Coentrão LM, Carneiro ÂV, Rocha-Sousa A, Brandão E, et al. Evaluation of visual acuity, macular status and subfoveal choroidal thickness changes after cataract surgery in eyes with diabetic retinopathy. *Retina.* 2015; 35:294-302.
- Kim SJ, Equi R, Bressler NM. Analysis of macular edema after cataract surgery in patients with diabetes using optical coherence topography. *Ophthalmology.* 2007; 114:881-9.
- Torrón-Fernández-Blanco C, Ruiz-Moreno O, Ferrer-Novella E, Sánchez-Cano A, Honrubia-López FM. Pseudophakic cystoid macular edema. Assessment with optical coherence tomography. *Arch Soc Esp Ophthalmol.* 2006; 81:147-53.
- Mentes J, Erakgun T, Afrashi F, Kerici G. Incidence of cystoid macular edema after uncomplicated phacoemulsification. *Ophthalmologica.* 2003; 217:408-12.
- Raosoftware, Inc. Sample Size Calculator. [Online] [cited 2015 January 1]. Available from: URL: <http://www.raosoftware.com/samplesize.html>
- Diabetic Retinopathy Clinical Research Network Authors/Writing Committee, Baker CW, Almkhatar T, Bressler NM, Glassman AR, Grover S, et al. Macular edema after cataract surgery in eyes without preoperative central-involved diabetic macular edema. *JAMA Ophthalmol.* 2013; 131:870-9.

19. Ferris FL 3rd, Miller KM, Glassman AR, Beck RW; Diabetic Retinopathy Clinical Research Network. A proposed method of logarithmic transformation of optical coherence tomography data for use in clinical research. *Ophthalmology*. 2010; 117:1512-6.
  20. Romero-Aroca P, Fernandez-Ballart J, Almena-Garcia M, Mendez-Marin I, Salvat-Serra M, BuilCalvo JA. Nonproliferative diabetic retinopathy and macular edema progression after phacoemulsification: prospective study. *J Cataract Refract Surg*. 2006; 32:1438-44.
  21. Somaiya MD, Burns JD, Mintz R, Warren RE, Uchida T, Godley BF. Factors affecting visual outcomes after small-incision phacoemulsification in diabetic patients. *J Cataract Refract Surg*. 2002; 28:1364-71.
  22. Eriksson U, Alm A, Bjarnhall G, Granstam E, Matsson AW. Macular edema and visual outcome following cataract surgery in patients with diabetic retinopathy and controls. *Graefes Arch Clin Exp Ophthalmol*. 2011; 249:349-59.
  23. Dowler JG, Sehmi KS, Hykin PG, Hamilton AM. The natural history of macular edema after cataract surgery in diabetes. *Ophthalmology*. 1999; 106:663-8.
  24. Krepler K, Biowski R, Schrey S, Jandrasits K, Wedrich A. Cataract surgery in patients with diabetic retinopathy: visual outcome, progression of diabetic retinopathy, and incidence of diabetic macular oedema. *Graefes Arch Clin Exp Ophthalmol*. 2002; 240:735-8.
  25. Flesner P, Sander B, Henning V, Parving HH, Dornonville de la Cour M, Lund-Andersen H. Cataract surgery on diabetic patients. A prospective evaluation of risk factors and complications. *Acta Ophthalmol Scand*. 2002; 80:19-24.
  26. Dowler JG, Hykin PG, Hamilton AM. Phacoemulsification versus extracapsular cataract extraction in patients with diabetes. *Ophthalmology*. 2000; 107:457-62.
-